

Management of Peutz-Jeghers Syndrome in Children and Adolescents: A Position Paper From the ESPGHAN Polyposis Working Group

*Andrew Latchford, †Shlomi Cohen, ‡Marcus Auth, §Michele Scaillon, ||Jerome Viala, ¶Richard Daniels, #Cecile Talbotec, **Thomas Attard, ††Carol Durno, and *Warren Hyer

ABSTRACT

Peutz-Jeghers syndrome (PJS) is a well-described inherited syndrome, characterized by the development of gastrointestinal polyps, and characteristic mucocutaneous freckling. Development of small bowel intestinal polyps may lead to intussusception in children may require emergency laparotomy with potential loss of bowel. Gastrointestinal polyps may lead to bleeding and anemia. This European Society for Paediatric Gastroenterology Hepatology and Nutrition position paper provides a guide for diagnosis, assessment, and management of PJS in children and adolescents and guidance on avoiding complications from PJS or from the endoscopic procedures performed on these patients. This is the first position paper regarding PJS published by European Society for Paediatric Gastroenterology Hepatology and Nutrition. Literature from PubMed, Medline, and Embase was reviewed and in the absence of evidence, recommendations reflect the opinion of pediatric and adult experts involved in the care of polyposis syndromes. Because many of the studies that form the basis for the recommendations were descriptive and/or retrospective in nature, some of the recommendations are based on expert opinion. This position paper will be helpful in the appropriate management and timing of procedures in children and adolescents with PJS.

Key Words: adolescent, child, colonoscopy, colorectal cancer, Peutz-Jeghers syndrome, polyposis

(JPGN 2019;68: 442–452)

Received July 12, 2018; accepted November 21, 2018.

From the *St Mark's Hospital Polyposis Registry, Harrow, UK, the †Dana-Dwek Children's Hospital, Tel Aviv Sourasky Medical Center, Tel Aviv, Israel, the ‡Alderhey Children's Hospital, Liverpool, UK, the §Hôpital Universitaire des Enfants Reine Fabiola, Brussels, Belgium, the ||Hôpital Universitaire Robert-Debré, Paris, France, the ¶Chelsea and Westminster Hospital, Chelsea, UK, the #Hôpital Necker-Enfants Malades, Paris, France, the **Children's Mercy Hospital, Kansas City, MO, and the ††Department of Paediatrics, Zane Cohen Centre for Digestive Diseases, Mount Sinai Hospital and The Hospital for Sick Children, University of Toronto, Toronto, Canada.

Address correspondence and reprint requests to Dr Warren Hyer, MB FRCPCH, Consultant Paediatric Gastroenterologist, St Mark's Hospital Polyposis Registry, St Mark's Hospital, Watford Rd, Harrow HA1 3UJ, UK (e-mail: polyposiswg@drhyer.co.uk).

ESPGHAN is not responsible for the practices of physicians and provides guidelines and position papers as indicators of best practice only. Diagnosis and treatment is at the discretion of physicians.

The authors report no conflicts of interest.

Copyright © 2018 by European Society for Pediatric Gastroenterology, Hepatology, and Nutrition and North American Society for Pediatric Gastroenterology, Hepatology, and Nutrition

DOI: 10.1097/MPG.0000000000002248

What Is Known

- There are published guidelines for the management of Peutz-Jeghers syndrome predominantly for adults. In paediatric practice, there is no consensus regarding timing of predictive testing or gastrointestinal surveillance.
- Peutz-Jeghers syndrome historically leads to a 68% risk of small bowel intussusception in children younger than 18 years.

What Is New

- We provide clear recommendations regarding the diagnosis, assessment, gastrointestinal surveillance, and strategies to reduce the risk of emergency laparotomy in children and adolescents affected by Peutz-Jeghers syndrome based on evidence where available.
- This position paper represents a useful practical guide to assist the paediatric gastroenterologist involved in the care of paediatric polyposis syndromes.

The aim of this evidence-based and consensus-based position statement, commissioned by the European Society for Paediatric Gastroenterology Hepatology and Nutrition (ESPGHAN) is to provide a comprehensive review of the diagnosis and management of Peutz-Jeghers syndrome (PJS) in paediatric patients. This position statement addresses the issue of complications of PJS, role and timing of endoscopic surveillance and polypectomy, and risk of cancer. This article is not a comprehensive overview of PJS and its complications.

This undertaking is the first position paper published on PJS in the paediatric age group. Our aspiration is that the guideline may lead to a degree of standardization in the approach and management of PJS thereby contributing to excellence and correct timing of surveillance and treatment with polypectomy in affected children. This article represents the basis for further data collection and research to develop a more robust paediatric evidence base to guide future decisions regarding managing this polyposis syndrome, with a view to updating this advice in 3 years.

METHODS

ESPGHAN commissioned position papers on polyposis syndromes in 2016. Three task force leaders (W.H. for familial adenomatous polyposis, S.C. for juvenile polyposis syndrome,

and A.L. for PJS) invited the listed authors to participate in the project. The key questions were prepared by the coordinating team working group in face to face meetings in 2016 and 2017 and then approved by the other members. Each task force performed a systematic literature search to prepare evidence-based and well-balanced statements on their assigned key questions. Searches were performed in PubMed and/or EMBASE and/or Medline and/or Cochrane (publication year from 2000 to 2017) or before if needed, including as a minimum the key words “paediatric,” or “adolescent” or “teenage” and “Peutz-Jeghers syndrome.” Case reports, articles in languages other than English were excluded. When insufficient information or publications were available in specific paediatric or adolescent papers then the search was broadened to include publications regarding adult patients. References in these documents were also searched to ensure acquisition of relevant source data. In the absence of evidence we relied on the expert opinion and personal practice of the authors. Expert opinion was sought from paediatric gastroenterologist with extensive expertise in PJS, adult gastroenterologist, and surgeons with expertise in polyposis syndromes.

All articles identified by the searches were selected by title or abstract. The abstracts and then the full publications were reviewed. Although PJS is a rare condition, most articles were not amenable for consistent grading by the level of evidence and strength of recommendation according to the GRADE system (Grading of Recommendations Assessment, Development and Evaluation). Many articles were case series, with its attendant report bias. International guidelines were reviewed, and their evidence and referenced articles were also assessed. Each task force proposed statements on their assigned key questions which were discussed by email exchange or face-to-face meetings and voted on during the subsequent year. In April 2018, a draft prepared by W.H. was sent to all group members and then subsequently modified. In ESPGHAN 2018, all members of the faculty discussed and reworded the final manuscript, and voted on the recommendations included in this article.

The manuscript was then submitted to the *Journal of Paediatric Gastroenterology and Nutrition* for publication in full length.

INTRODUCTION

PJS is an inherited polyposis syndrome in which multiple characteristic polyps occur in the gastrointestinal (GI) tract, associated with mucocutaneous pigmentation, especially of the vermilion border of the lips. It is inherited in an autosomal dominant manner and is caused by a germline mutation in the *STK11 (LKB1)* gene. The incidence of this condition is estimated to be up to 1 in 200,000 live births (1).

Mucocutaneous pigmented lesions are seen in around 95% of patients and may be the first clue to an individual having PJS. Such lesions tend to arise in infancy, occurring around the mouth, most typically but may be seen at other sites such as nostrils, perianal area, fingers and toes, and the dorsal and volar aspects of hands and feet. They may fade after puberty but tend to persist in the buccal mucosa. Lip freckling is not unique to PJS and is seen in other conditions.

The polyps seen in PJS have characteristic histological features and should be easily identified. Frond-like elongated epithelial component is observed along with cystic gland dilatation and smooth muscle arborization. PJS polyps are usually referred to as hamartomas, but their origin is not clear. PJS polyps may display the phenomenon of “pseudo-invasion,” which may be mistaken for invasive carcinoma, although the lack of cytological atypia, among other features, can distinguish between true and pseudoinvasion.

PJS polyps are found throughout the GI tract. They may also be found at extraintestinal sites such as the gallbladder, bronchi, bladder, and ureter. GI polyps may cause GI bleeding, anaemia, and abdominal pain due to intussusception, obstruction, or infarction. The

most common and concerning manifestation in children and adolescents is the presentation with small bowel intussusception with its attendant risk of bowel infarction and subsequent resection. It is widely accepted that there is an increased risk of many cancers in PJS.

In a single individual, a clinical diagnosis of PJS may be made when any one of the following is present:

1. Two or more histologically confirmed PJS polyps
2. Any number of PJS polyps detected in 1 individual who has a family history of PJS in close relative(s)
3. Characteristic mucocutaneous pigmentation in an individual who has a family history of PJS in close relative(s)
4. Any number of PJS polyps in an individual who also has characteristic mucocutaneous pigmentation.

Molecular Genetics of Peutz-Jeghers Syndrome

Initial linkage analysis localized the affected gene to chromosome 19p13.3 and subsequently the gene was identified, which encodes a serine-threonine kinase, *STK11 (LKB1)*. Loss of heterozygosity at 19p13.3 seen in PJS polyps and malignancy suggests that *STK11* acts as a tumour suppressor gene. The gene extends over 9 exons, exceeds 23 kb in length and encodes a 433 amino acid protein, whose function is complex and remains incompletely understood. It is expressed ubiquitously in adult and foetal tissue. It appears to have a role in regulation of cellular proliferation and apoptosis, cell polarity, regulation of the Wnt signalling pathway, cell metabolism, and energy homeostasis. It is an upstream regulator of adenosine monophosphate-activated protein kinase-activated protein kinase and acts as a negative regulator of the mTOR (mammalian target of rapamycin) pathway. The mTOR pathway is particularly important as it is a final common pathway that is also dysregulated by other hamartomatous polyposis syndromes caused by germline *PTEN*, *BMPRIA*, and *SMAD4* mutations.

Although genetic heterogeneity has been questioned, no clear second causative gene has been found for PJS cases without a detectable *STK11* mutation. It is likely that with continued improvements genetic testing that mutation detection rates will improve further, making genetic heterogeneity even less likely. Of those who meet the clinical criteria for PJS, more than 94% had a mutation detected (64% point mutation, 30% deletions) (2).

No clear genotype-phenotype correlation has been demonstrated in PJS. Furthermore there have been no clear clinical differences found between cases with and without detectable germline *STK11* mutations.

Recommendation 1. At what age should predictive genetic testing be undertaken in at risk children?

Recommendation 1

Predictive genetic testing for an asymptomatic at risk child should be offered from age 3 years and should be performed earlier in a symptomatic at risk child. (moderate recommendation, low-quality evidence, agreement 90%)

PJS is inherited in an autosomal dominant pattern, so children of affected parents can be referred for predictive genetic testing before onset of symptoms. Predictive testing for a genetic disorder should be

ideally delayed until an age when the disease will become apparent and when the result will affect on the patient management or when an intervention may be considered. Predictive genetic testing can only be performed where the family mutation has been identified in the affected parent. If no pathogenic gene mutation has been identified in an affected parent, then the child cannot undergo predictive genetic testing. Current international guidelines have not proposed a specific age at which to perform predictive genetic testing (3).

Small bowel intussusception is the most significant risk in childhood and interventions are available to reduce the risk of this emergency occurrence. The age of first intussusception is variable and may rarely occur in the first few years of life. The age at which predictive genetic testing should be performed will be heavily influenced by intussusception risk, and should precede this possible event allowing appropriately timed GI surveillance. Historical data have shown that 68% of patients with PJS have undergone a laparotomy for intussusception by age 18 years (4). Predictive genetic testing will assist the clinician to interpret abdominal symptoms in an at risk child, for example, pain and vomiting. Finding a pathogenic mutation in an at-risk child would lead to earlier GI investigation in a symptomatic child, with a view to interventions that would thereby reduce the risk of emergency intussusceptions. The presence of classical mucocutaneous pigmented lesions would confirm the diagnosis, even before predictive testing but may not be present in the first few years of life or may be subtle or even absent even in an individual with a genetic diagnosis of PJS; therefore, absence of such lip freckling alone cannot wholly exclude PJS.

Genetic testing can be performed on blood or a buccal sample and therefore acceptable options exist for testing at a young age. Given the wide spectrum of age at which laparotomy was required in childhood (4), and whilst intussusceptions can occur as young as infancy, the recommendation to undergo genetic testing at age 3 years onwards in an asymptomatic child seems a pragmatic approach in the absence of more robust evidence. If an at-risk child younger than 3 years is symptomatic with rectal bleeding or pain, then such testing should be performed at a younger age. All families who undergo predictive genetic testing should receive counselling regarding the implications of a positive or negative result.

Recommendation 2. What is the risk of PJS in children with mucosal freckling? What investigations should be performed in a child with mucosal freckling suggestive of PJS?

Recommendation 2

Lip and mucosal freckling is not diagnostic of PJS alone. Patients with lip and mucosal freckling suggestive of PJS should be referred to a geneticist for diagnostic genetic testing. Investigation of the GI tract is recommended to start no later than age 8 unless symptoms arise earlier. (weak recommendation, low-quality evidence, agreement 100%)

What is the Risk of PJS in Children With Mucosal Freckling Without A Relevant Family History Of Polyposis?

There are no data to allow an estimation of risk of PJS in a child who presents with mucosal freckling alone. In PJS the

freckles are small, dark brown, oval or circular macules most commonly on the lips (lower more than upper), gums, oral mucosa, and hard palate. These macules (also called lentiginosities) are concentrated around the nose and perioral region. Mucosal freckling is not pathognomonic for PJS and conditions including Carney complex (5) and LEOPARD (6) syndrome are among the differential diagnoses.

The phenotype in PJS can be quite variable. The mucocutaneous pigmentation in PJS typically appears in infancy and may fade after puberty. Children referred with freckling alone should be assessed for non-GI manifestations of PJS and examination for features of intussusception. The clinical diagnostic criteria are important; in a single individual, a clinical diagnosis of PJS may be made when the criteria listed above in the introduction are fulfilled. Therefore, in the absence of a family history of PJS and without documentation of PJS polyps, a clinical diagnosis of PJS cannot be made on the basis of lip freckling alone (Fig. 1).

What Investigations Should Be Performed in a Child With Mucosal Freckling Suggestive of PJS?

If a child has typical mucocutaneous pigmentation suggestive of PJS, further investigations are required to determine whether or not a clinical diagnosis can be made. The diagnostic criteria are described above. If there is a family history of PJS then a clinical diagnosis of PJS can be made. The child would then be eligible for diagnostic genetic testing and should be enrolled in a GI surveillance programme as described in recommendation 3.

Diagnostic genetic testing should also be offered to those in whom the freckling is highly suggestive of PJS. This testing should be performed after seeing a geneticist or receiving genetic counselling from an appropriately qualified clinician. Identifying a pathogenic germline variant in an individual with a clinical diagnosis of PJS is possible in 95% of cases (2). The interpretation of a normal genetic result, whereby no germline variant of PJS is identified, in the absence of a clinical diagnosis is difficult, as it will not exclude a diagnosis of PJS. The finding of a definite pathogenic variant will make a genetic diagnosis even in the absence of a clinical diagnosis. If a variant of unknown significance is found then again it creates great difficulty in knowing how to manage the patient, as a diagnosis of PJS can neither be made nor refuted. Therefore in those patients presenting with typical or highly suggestive mucocutaneous pigmented lesions, it is recommended to perform GI investigations and diagnostic genetic testing in parallel.

In the absence of a family history or a predictive genetic result it is necessary to investigate the GI tract to establish whether or not a diagnosis of PJS can be made. The small bowel is the site in which polyps are most likely to be found, followed by the colon. The question then arises as to when the GI tract assessment should be performed. If child has a genetic diagnosis of PJS, then GI tract surveillance is recommended to start no later than age 8 (see recommendation 3). Therefore delaying the GI tract assessment in a child with mucocutaneous pigmented lesions alone until this age would be reasonable (Fig. 2). However, if the child has any GI symptoms suggestive of PJS polyposis then earlier investigation would be recommended, due to the risk of small bowel intussusception in childhood. The preferred imaging of the GI tract would be gastroscopy, colonoscopy, and video capsule endoscopy (VCE) or magnetic resonance enterography (MRE) (see recommendation 3) (Figure 1).

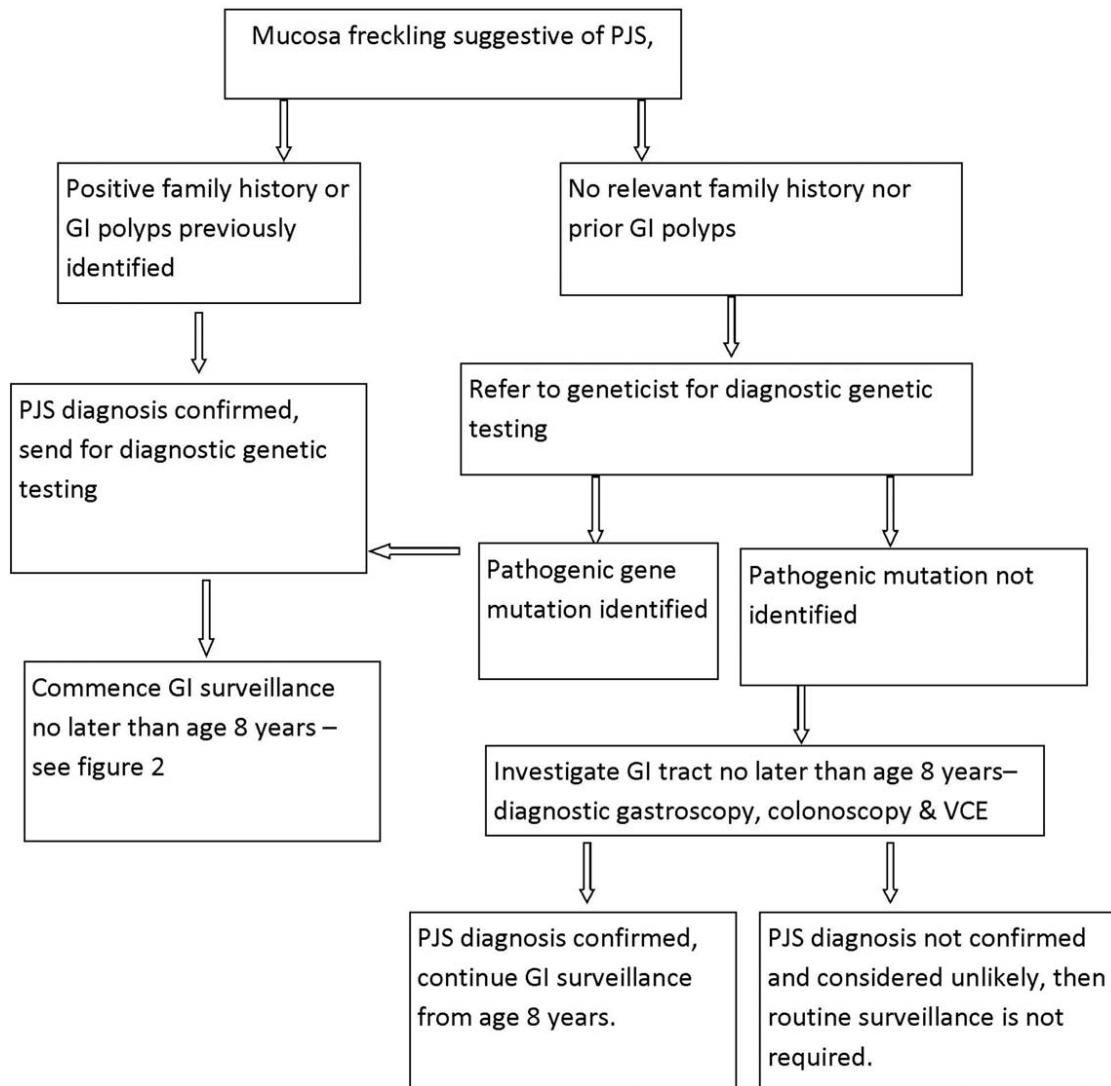


FIGURE 1. Management of a child with mucosal freckling suggestive of PJS. GI = gastrointestinal; PJS = Peutz-Jeghers syndrome; VCE = video capsule endoscopy.

Recommendation 3. At what age should gastrointestinal surveillance commence in a child with PJS and what investigations should be performed?

Recommendation 3
 Gastrointestinal surveillance by upper GI endoscopy, colonoscopy and VCE should commence no later than 8 years in an asymptomatic individual with PJS, and earlier if symptomatic. These investigations should generally be repeated every 3 years. Earlier investigation of the GI tract should be performed in symptomatic patients. Timing for GI surveillance needs to be individualized, and the parents should receive adequate counselling regarding the age to commence GI surveillance. (moderate recommendation, low-quality evidence, agreement 90%)

In adult patients with PJS, the majority of GI polyps are located in the small bowel and similarly in paediatric studies, with the distribution of polyps has been reported, with 36%, 50%, and 21% of polyps in stomach, small bowel, and colon, respectively (7). Approximately 95% of intussusceptions occur in the small bowel, 5% in the colon and generally were caused by hamartomas >15 mm in diameter (median size 35 mm) with polyp size probably being the most important risk factor for small bowel intussusception (8).

Any surveillance strategy must take into account the morbidity and risks of the tests, and the risks incurred by subsequent polypectomy were this deemed to be necessary. There is currently only adult data suggesting that strategies to survey the small bowel with polypectomy decrease the risk of intussusception and emergency laparotomy (9,10).

The greatest risk to children with PJS is related to polyp associated complications especially to small bowel intussusception. The cumulative intussusception risk is estimated at 50% to 68% during childhood (4,8) with 15% to 30% requiring surgery before the age of 10 years. The median age of the first

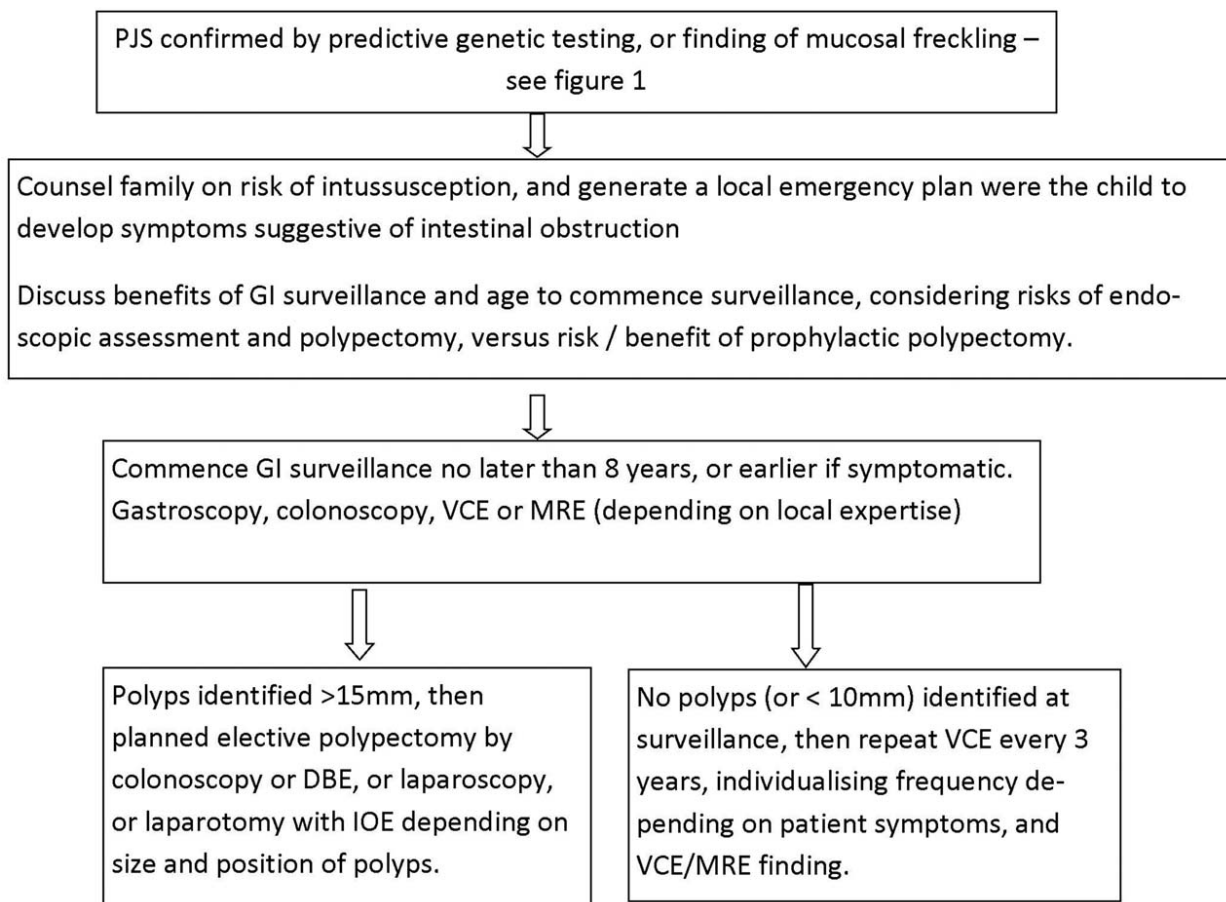


FIGURE 2. Recommended GI surveillance strategy in children with PJS. DBE = double-balloon enteroscopy; GI = gastrointestinal; IOE = intraoperative enteroscopy; MRE = magnetic resonance enterography; PJS = Peutz-Jeghers syndrome; VCE = video capsule endoscopy.

intussusception is 10 to 16 years, with the earliest episodes occurring at 1 to 5 years. These data need to be interpreted with caution as they include patients who preceded routine small bowel surveillance. In addition, these reports mix patients with an established diagnosis of PJS undergoing surveillance, with patients in whom the diagnosis of PJS is only made at the time of presentation with an intussusception.

What Is the Age to Commence Gastrointestinal Surveillance.

GI surveillance options need to be offered early enough to locate the small bowel polyps, and enable polypectomy to prevent laparotomy and its attendant complications including loss of small bowel. On the contrary when selecting the preferred age to commence a GI surveillance programme in paediatrics, harm from invasive screening strategies at a young age, with the attendant complication risk from colonoscopy and polypectomy in small children has to be considered.

One paediatric review proposed that screening should be considered at 10 years (11). After a systematic review in 2010, consensus international guidelines recommended commencing intestinal surveillance from the age of 8 years (3).

There are published cohort studies proving the benefit of GI surveillance in preventing laparotomy in PJS and it is logical that earlier detection and resection of a PJS polyp in the small bowel could avoid an emergency procedure (9).

The timing of any surveillance needs to be individualized according to multiple considerations including symptoms, and family perspective. After careful debate and consideration of the issues, and with the absence of any paediatric data other than from case series, the working group recommendation is that small bowel GI surveillance by VCE or MRE should be performed no later than age 8 years, and earlier if symptomatic. This age was selected taking into account the historical risk of intussusception and to limit invasive investigations which may be unnecessary in the majority of at risk young children. Parents should be advised that historical data describes a cumulative intussusception risk of only 15% to 20% at 10 years of age, and it is likely that many of these patients had relevant symptoms predating the intestinal obstruction. Therefore, if parents know to report symptoms to the clinician, delaying routine surveillance in an asymptomatic child until age 8 years would be reasonable. Any child at risk from PJS (family history or lip freckling) who presents at any age, even before age 8 years, with symptoms of intestinal polyps such as pain, bleeding, anaemia, poor weight gain, or intestinal obstruction merits GI investigations.

The patient and their parent should receive adequate counselling regarding the age to commence GI surveillance. This will include the risk versus benefit of invasive procedures with anaesthetic, and considering the benefits of GI surveillance and polypectomy.

Which Investigation Modalities Should Be Used to Assess the Gastrointestinal Tract?

Gastroscopy and colonoscopy are the preferred investigation to assess the upper GI tract and colon, respectively (12). In the historical series describing emergency intussusception, assessing small bowel in patients especially in children was hampered by the inability to assess the small bowel mucosa in detail. This was overcome by the availability of VCE and MRE.

Polyp detection with VCE is reported to be superior than radiological examination (13,14). VCE was considered more comfortable than MRE by adults (15). One retrospective paediatric study reported a high detection rate of PJS polyps in children finding polyps in 12 of 14 who subsequently underwent endoscopies, double-balloon enteroscopy (DBE) or intraoperative enteroscopy (IOE) (16). VCE, however, has some limitations with reported lower detection rate for polyps in the duodenum and proximal jejunum secondary to faster transit, the frequent bubbles in this part of the digestive tract and a limited bowel distension. For this reason most patients are offered some bowel preparation before VCE insertion. Several adult studies reported that VCE could miss large polyps compared to DBE (17–19). In addition, one of the downsides of VCE is its inability to accurately localize polyps in the different parts of the small bowel and poorly assess the polyp size (20).

Children older than 8 years are generally able to swallow the device; in those younger than 8 years VCE has to be endoscopically deployed in the duodenum via gastroscopy in younger children (21) usually at the same time as other endoscopic surveillance. Fears about the VCE becoming impacted into the small bowel of children are unjustified. VCE can be usually performed in 2-year-old children (21,22). In a retrospective review of 284 paediatric VCE studies for various indications of which 2% were for polyposis, capsule retention occurred in 1.8%. Patency capsules were applied in 23 patients, which allowed the VCE to proceed in 19 patients, with 1 retained capsule (23). Patency capsules are not required to be used routinely, as polyps themselves do not infer a significant risk of capsule retention. If a child, however, has had previous abdominal surgery, then the use of a patency capsule is recommended to reduce risk of retention.

MRE does not require the child to swallow a VCE or undergo anaesthesia to deploy the capsule. In the largest adult study, MRE may have a better diagnostic yield for >15 mm polyps (15), although this conclusion is conflicting with other smaller adult studies (13,24). To better distend the small bowel, enteroclysis technique may be required, and such large volumes of fluid might require a nasogastric tube or nasojejunal tube to be placed under x-ray fluoroscopy (25). Such additional intervention clearly would increase the handling and misery of the procedure. MRE with enteroclysis can still miss some large polyps in adults (26).

There is a role of small bowel ultrasound in PJS. It is particularly useful in symptomatic patients for identifying intussusception and in slim children, the lead polyp may be visualized.

Using ultrasound for screening for small bowel polyps as part of PJS surveillance is less useful. Early reports studied capability of ultrasonography to detect polyps after colonic filling by enema but this technique is invasive, especially in children and frequently misses polyps compared with colonoscopy limiting its use in GI surveillance. There are no reports studying the usefulness of ultrasonography to detect small bowel polyps as part of surveillance for PJS, and it is therefore not recommended for this indication.

Computed tomography (CT) scanning is an effective tool for assessing small bowel tumours, including polyps, but like MRE, requires enteroclysis, with sensitivity and specificity assessed up to 93% and 99%, respectively in adults (27). With its attendant risk from radiation exposure, CT scan should be reserved for PJS patients with acute intestinal obstruction from intussusception only after ultrasound has been performed and diagnostic uncertainty persists.

Balloon-assisted enteroscopy (BAE), DBE, or single-balloon enteroscopy is an endoscopic procedure that allows examination and therapeutic polypectomy throughout the small bowel. In expert hands, and in a favourable abdomen large enough to accommodate the balloon enteroscope, the whole of the small bowel can be assessed at BAE, from oral and then rectal route (17). An adult study compared 38 DBE to 34 VCE and 38 fluoroscopic enteroclysis (28), the detection rate of polyp was similar for the 3 techniques. DBE can, however, observe polyps that were missed by VCE or imaging (20). Paediatric series confirm that DBE is feasible in PJS children (12). BAE, however, should not be recommended as a surveillance tool as it is technically challenging, limited by size of the abdomen, and requires both oral and rectal approaches to visualize the whole length of the small bowel. The main role of BAE is therapeutic, for targeted polypectomy.

In summary, gastroscopy, colonoscopy, and VCE deployed at gastroscopy is the most sensitive and effective way to assess the whole GI tract and should be commenced no later than age 8 years, or earlier if symptomatic (Fig. 2).

Recommendation 4. What is the preferred method of managing a symptomatic child with PJS presenting with intussusception and intestinal obstruction?

Recommendation 4

Patients with symptomatic intussusception should be urgently referred for surgical reduction. There is no role for radiological or endoscopic reduction of intussusception in a symptomatic child with intestinal obstruction from a PJS polyp. At laparotomy, patients should ideally undergo an intraoperative enteroscopy to clear the small bowel of other PJS polyps. (strong recommendation, low-quality evidence, agreement 100%)

Intussusception occurs when a proximal segment of bowel and its associated mesentery slides into the lumen of the adjacent distal segment leading to bowel obstruction, ischemia, necrosis, and perforation. In PJS, this is seen most commonly in the small bowel.

Retrospective data suggest a risk of intussusception and emergency laparotomy in 70% of patients with PJS by the age of 18 years, but this was before the introduction of a small bowel surveillance programme (4).

Intussusception in normal children may occur and reduce spontaneously. Those patients with PJS will invariably have a lead point for their intussusception, most commonly in their small bowel where the calibre of the bowel enables intussusceptions to develop and lead to the complications listed above. Children with a lead point such as a small bowel polyp have a substantially increased risk of requiring surgical operative management compared to those with spontaneous intussusception without a lead point (odds ratio 14.5, $P = 0.005$ 95% confidence interval, 2.3–90.9) (29).

In those children without a family history, intussusception is commonly the first recognized manifestation of PJS, with an acute presentation with obstructive symptoms or less acutely with recurrent abdominal pain. In PJS, the lead point for the intussusception is usually located in the small intestine (>90% of patients), predominantly in the jejunum but not exclusively (8,30). A child or adolescent presenting with intestinal obstruction from PJS should be referred urgently to a paediatric surgeon and most likely undergo laparoscopy or laparotomy urgently to avoid any loss of bowel from ischaemia. There is no validated nor confirmed role for attempting pneumatic reduction of a small bowel intussusception in PJS. Nor should DBE be used in acute intestinal obstruction from intussusception.

The risk of intussusception is thought to be related to polyp size. In a Dutch series of both adult and children with PJS, the intussusception were caused by polyps with a median size of 35 mm (range 15–60 mm) and located mainly in the small intestine, jejunal more often than ileal (8). Other than the presence of small bowel polyps and their size there are no other predictors to identify which patients with PJS will develop intussusception (31). Logic dictates that smaller children may develop intussusception with smaller polyps but there are no clear data to validate this presumption.

If imaging is required before surgery then transabdominal ultrasound should be considered the first choice and if diagnostic uncertainty persists either proceed to CT scan or laparoscopy.

At laparoscopy or laparotomy, the intussusception should be reduced, the lead point identified and the PJS polyp resected. Then the rest of the bowel should be assessed for PJS polyps. If data from prior investigations, for example, VCE is available, this will assist the surgeon in locating other PJS polyps. If other PJS polyps have been identified at surveillance previously, or surveillance has not been yet performed, the surgeon and paediatric gastroenterologist should together assess the remaining small bowel by IOE). As many as 40% of children and adolescents who required a laparotomy <18 years, required a second laparotomy within 5 years for a polyp related complication, half within 2 years of the first laparotomy (4). In adult series IOE and resecting small bowel polyps (the “clean sweep”) significantly reduces the risk of subsequent laparotomy (10,32). IOE requires expert skills in polypectomy and ideally should be performed by an endoscopist skilled in complex endoscopy. Such expertise is often available from adult colleagues.

In patients with PJS with intussusception identified incidentally either at routine abdominal examination or at surveillance, then their care should follow recommendation 5.

Recommendation 5. What is the role of endoscopic polypectomy in the asymptomatic child and adolescent found to have PJS polyps at surveillance?

Recommendation 5

Elective polypectomy should be performed to prevent polyp-related complications. Small bowel polyps >1.5 to 2 cm in size (or smaller if symptomatic) should be electively removed to prevent intussusception. Endoscopic, surgical, and combined approaches all have their merit and the choice of modality should be made on a case-by-case basis, depending on the site and size of the polyp and the endoscopic expertise available. (weak recommendation, low-quality evidence, agreement 100%)

For those patients identified to have PJS polyps at GI surveillance, then polypectomy should be considered to avoid intussusception, and thus potential loss of small bowel and complications from bleeding. Polypectomy is not required to reduce cancer risk; PJS polyps do not undergo malignant change in childhood.

There are no data detailing at what size polyps should be considered for resection in children with PJS. Current adult and paediatric recommendations suggest removing small bowel polyps 1.5 to 2 cm or more in size or smaller polyps if causing symptoms (3). It is not known what size polyps merit resection in children and adolescents but from the adult guidelines those above the 1.5 to 2 cm should be removed at polypectomy. Perhaps in smaller children (eg, <25 kg) smaller polyps may also confer a risk of intussusception.

In a review of 110 patients with PJS, the median size of polyp resulting in an intussusception was 35 mm, and 50% of patients developed an intussusception by the age of 20 years (8). In a paediatric cohort, median age at first identification of polyps was 8 years (range 1–18); “large polyps at 1 cm” were seen in 9 of 14 at a median age of 7 years (7). As the authors admit, their cohort is small and subject to significant ascertainment bias. In this cohort there was the high complication rate from endoscopic procedures (complications occurring 14/66 endoscopic procedures). This is in contrast to the safety profile of a larger single centre, which included adults and children with PJS and in which endoscopic complications were rare (9).

Options to remove a PJS polyp include endoscopy, laparoscopy, and laparotomy. Endoscopic polypectomy for PJS requires expertise and should only be performed by those expert in polypectomy. The risk of perforation from polypectomy in PJS may be higher than other GI polyps. Muscularis mucosa commonly invaginates into the large pedunculated stalk increasing the risk of perforation at electrocautery. Techniques to decrease the risk of perforation and bleeding need to be employed at polypectomy including mucosal lifting, postpolypectomy clips, and electro-surgical knife. The data regarding safety of endoscopy and polypectomy in children with PJS are sparse. The St Mark’s series was a mixture of adult and paediatric data and describes a much lower complication rate and certainly levels that are acceptable (9). The perforations described in this series were both in children and occurred while attempting to remove polyps >2 cm.

BAE offers the opportunity to remove small bowel polyps without the need for laparoscopy. There are more data emerging specifically regarding the safety of BAE. The studies contain small numbers and only one is from a dedicated paediatric cohort. Sakamoto reviewed their results from DBE polypectomy as an alternative to surgical intervention (33). In this cohort of 15 patients, undergoing up to 4 DBE sessions, there was 1 perforation and 2 cases each of bleeding and pancreatitis. In a different cohort of mixed adult and children with PJS, no endoscopic complications were observed (34). There is only 1 exclusively paediatric cohort who underwent single-balloon enteroscopy (35). The cohort size was small ($n = 10$) and the median age was 13.7 years. Twenty-three procedures were performed and 1 perforation was reported, along with 3 cases of postprocedural abdominal pain.

The risks and benefits of BAE in children may be different from those of the adult population. In particular as the mesentery is shorter and thinner, there is concern of an increased risk of traction injury during enteroscopy. Larger polyps may have a high risk of invaginating the muscularis into the stalk, so polypectomy will inevitably result in perforation. To overcome the risk of this, BAE can be combined with laparoscopy to observe the serosal surface at polypectomy and oversee perforations that develop and patients with larger small bowel polyps (eg, >3 cm) should be considered candidates for onward referral to centres with expertise in complex polypectomy able to offer this combined approach.

There are no data to advise on size of PJS polyps that merit polypectomy in the stomach nor colon, but endoscopic polypectomy in PJS carries a risk of complications. More data are required to specifically address the technical aspects of endoscopy and polypectomy in children with PJS. Small polyps, for example, 3 to 5 mm do not require removal. For larger polyps, the individual polyp should be assessed so that the optimal polypectomy strategy can be selected opting either for an endoscopic polypectomy requiring expert skills or perhaps a safe elective wedge laparoscopic resection.

Recommendation 6. What is the appropriate investigation pathway for boys with Sertoli cell tumours and PJS?

Recommendation 6

Large-cell calcifying Sertoli cell tumours of the testes (LCCSCTs) leading to feminizing manifestations including gynaecomastia are associated the PJS and males should be assessed for this at clinical assessment. Referral to a paediatric endocrinologist is required in those that develop LCCSCT. (moderate recommendation, low-quality evidence, agreement 100%)

LCCSCTs are associated with PJS, but the prevalence is unknown, with only reports from single-centre cohorts available (36). Most LCCSCTs have a benign clinical course, but malignancy can occur especially in older ages. LCCSCTs are first detected in the young, from prepubertal boys to young adults but tumours have been described as early as at 2 years of age. Because of the frequent higher expression of aromatase within these tumours, there is higher conversion of testosterone into estradiol.

Gynaecomastia, advanced skeletal maturation, and bilateral testicular enlargement are therefore the main clinical manifestations of LCCSCTs. LCCSCTs are often bilateral, present with an increase in the overall testicular volume, and their calcifications are palpable. As oestrogens advance skeletal maturation, LCCSCT in a

prepubertal boy may present with acceleration of his growth. This may not be considered initially as a worrisome clinical sign in a peripubertal child, as this is an expected pattern of growth when a child enters puberty. The continuous effects of estrogens will, however, eventually be noticed, as gynaecomastia may also develop. LCCSCTs are bilateral in 20% of the reported cases; they may be missed by physical examination, unless calcifications are palpable.

Testicular ultrasound can demonstrate bilateral enlargement in testicular volume, with or without microcalcifications. The characteristic “Christmas tree-like” appearance of multiple lesions in syndromic LCCSCTs is almost pathognomonic for this tumour.

There are few data regarding LCCSCTs in PJS. In a single-centre review of 14 children with PJS (10 boys) gynaecomastia was the reason for initial assessment in 1 (7%) and 2 boys were reported to have had LCCSCT at age 8 and 11 years (7).

In the light of the association between LCCSCT and PJS, children should have testicular examination at each clinical assessment, with assessment of growth, height velocity, and examination to look for gynaecomastia. Testicular ultrasound has been advocated from the age of 4 years in boys every 2 years until 12 years of age, but no evidence exists on the effectiveness of this strategy or its implications on treatment options.

Those identified to develop physical manifestations of LCCSCT or gynaecomastia should be referred to a paediatric endocrinologist to confirm the diagnosis and consider other causes of gynaecomastia. Treatment options for LCCSCT are controversial, there is no consensus, and expert advice should be obtained. These include the use of aromatase inhibitor therapy in prepubertal boys with LCCSCTs, or breast reduction surgery. Because of the rarity of this condition, patients with Sertoli cell tumours should be referred to and are best managed by a specialist paediatric endocrinologist.

Recommendation 7: What is the role for pharmacological agents in PJS in children?

Recommendation 7

There is no role for pharmacological agents as a treatment or for chemoprevention in PJS. (strong recommendation, low-quality evidence, agreement 100%)

There are no paediatric studies using chemopreventive agents to prevent polyp formation or regression nor prevention of cancer.

Studies in mice have shown papamycin, a macrolide used in immunosuppression to be effective in reducing polyp number and size in a murine model of PJS (37). An estimated dose of $1.5 \text{ mg} \cdot \text{kg}^{-1} \cdot \text{day}^{-1}$ showed no side effects, but was statistically significant in reducing polyp burden in mice when given daily over a prolonged period, initiating treatment before the onset of polyposis. However given that it is not established, indeed is unlikely, that cancer in PJS arises from the PJS polyp, studies using polyp number and size as an endpoint for a chemoprevention study will not address the key questions which is whether or not they can reduce the risk of cancer. It is unclear if this drug can reduce the risk of polyp-related complications (such as intussusception) but carefully designed human studies will be required, which given the rarity of PJS, such a clinical trial is unlikely to be performed.

Everolimus is also being studied as a potential agent for PJS. There are case reports of its use (without any conclusions able to be drawn) and also ongoing studies in its utility in the setting of advanced malignancy. There are, however, no data regarding its potential as a chemoprevention agent (38).

To date, no human trials exist for any chemoprevention strategy in PJS and therefore chemoprevention or pharmacological agents to manage PJS cannot be recommended.

Recommendation 8: What is the cancer risk in children and young adults with PJS?

Recommendation 8

Cancer in children with PJS is an extremely rare event. Children and adolescents should be routinely clinically examined for features of sex cord tumours. (Moderate recommendation, moderate-quality evidence, agreement 100%)

Carcinogenesis and the role of the PJS polyp is an area which remains controversial. Although some postulate a hamartoma-adenoma-carcinoma sequence, there is some evidence of polyclonality (which would go against these polyps having a malignant potential) and indeed in a single-centre series of almost 2500 polypectomies, dysplasia/atypia was seen in only 6 (0.24%) (9).

It is widely accepted that there is an increased risk of many cancers in PJS. The majority of the literature on cancer risk in PJS comprises multiple single cohort studies. Most are small and carry inherent bias and so drawing meaningful conclusions from them is difficult and they are likely to overestimate cancer risk. A meta-analysis has been performed by Hearle et al (39) creating a cohort of 419 patients with PJS. This offers the most comprehensive data for cancer risk and their main findings are summarized in Table 1. Interestingly more recent data, however, seem to support that GI cancers are less of a clinical problem and that pancreatic and breast cancers are the most commonly seen cancers in PJS (9).

The best data reflecting cancer risk are summarized in an International Guideline paper in 2010 with a proposed risk ranging from 9% to 39% depending on site and publication (3). One of the most notable features is the rapid increase in risk from the age of 50 years (3,39).

Sex cord tumours of the ovaries are a rare but important tumour with low malignant potential, in females with PJS. The best data regarding this tumour comes from a historical series of 74 patients recorded to have ovarian sex cord tumours of which 27 were in patients with PJS and all the PJS-related tumours were multifocal, bilateral, very small, calcified, and benign (40). They can, however,

TABLE 1. Summary of cancer risk in Peutz-Jeghers syndrome—adapted from Hearle et al (39)

Type of cancer	Cancer risk by age %					
	20 y	30 y	40 y	50 y	60 y	70 y
All cancers	2	5	17	31	60	85
Gastrointestinal	—	1	9	15	33	57
Breast (female)	—	—	8	13	31	45
Gynaecological	—	1	3	8	18	18
Pancreas	—	—	3	5	7	11

affect children and the youngest was reported at 4 years of age. It has been estimated that 36% of patients with sex cord tumours of the ovaries have PJS (41). A Sertoli-Leydig cell ovarian tumour was reported in a 2-year-old girl with precocious puberty and gastric polyps as early manifestation of PJS as the earliest published report of malignancy in a child with PJS (42). A malignant ovarian neoplasm in a 16-year-old girl has been reported (43). Two other childhood cancers were also reported in this cohort of 133 Dutch patients.

Other childhood cancers were historical cases of small bowel cancer but these data are hard to validate and epithelial misplacement in small bowel polyps is a finding which has historically caused confusion and lead to an incorrect diagnosis of cancer (44). From the published data, cancer in childhood in PJS is exceptionally rare and limited to infrequent case reports. Malignancy appears restricted to adults. Paediatric patients and their families can be reassured that the cancer risk is exceptionally low, and for GI malignancies there are no documented cancers in children with PJS. Investigations to screen for cancers in childhood are unnecessary. Children and adolescents should be routinely examined for features of sex cord tumours, for example, abdominal mass, or feminization.

WHO SHOULD CARE FOR CHILDREN AND ADOLESCENTS WITH PJS?

Managing patients with an inheritable GI condition with surgical childhood complications, and involving family members, requires an expert multidisciplinary team available in a polyposis registry. The registries provide care across the generations to affected family members, and schedule surveillance and screening investigations ensuring timely investigations. Within the team, the polyposis registry will have access to endoscopists with expert skills in advanced polypectomy.

Polypectomy in children with may confer a higher risk compared to adults, with case series identifying that children and adolescents have a greater risk of perforation compared to affected adults. One series identified a significant complication rate in children and adolescents (7) compared to a larger cohort of predominately adult patients (9). The risk of perforation and post-polypectomy complications is related to the skill and expertise of the operator, and such polypectomies should only be performed by those with training and accreditation in polypectomy (45). Physicians responsible for the care of children and adolescents with PJS should ideally be affiliated or have access to a polyposis registry; the local genetics unit will be in a position to signpost a clinician to the appropriate facility (Table 2).

SUMMARY OF RECOMMENDATIONS

Recommendation 1

Predictive genetic testing for an asymptomatic at risk child should be offered from the age of 3 years and should be performed earlier in a symptomatic at-risk child.

(moderate recommendation, low-quality evidence, agreement 90%)

Recommendation 2

Lip and mucosal freckling is not diagnostic of PJS alone. Patients with lip and mucosal freckling suggestive of PJS should be referred to a geneticist for diagnostic genetic testing. Investigation of the GI tract is recommended to start no later than age 8 unless symptoms arise earlier.

(weak recommendation, low-quality evidence, agreement 100%)

TABLE 2. Areas requiring research in the field of Peutz-Jeghers syndrome in children

What is the natural history of PJS in children, specifically identifying those patients who have few or insignificant polyps in childhood?
In the era of predictive genetic testing, and small bowel surveillance, what is the current prevalence and age of intussusception and emergency laparotomy?
The need for new effective pharmacological treatments?
What is the role of a future colon specific video capsule in colonic surveillance in children with PJS?

PJS = Peutz-Jeghers syndrome.

Recommendation 3

GI surveillance by upper GI endoscopy, colonoscopy, and VCE should commence no later than 8 years in an asymptomatic individual with PJS, and earlier if symptomatic. These investigations should generally be repeated every 3 years. Earlier investigation of the GI tract should be performed in symptomatic patients. Timing for GI surveillance needs to be individualized, and the parents should receive adequate counselling regarding the age to commence GI surveillance.

(moderate recommendation, low-quality evidence, agreement 90%)

Recommendation 4

Patients with symptomatic intussusception should be urgently referred for surgical reduction. There is no role for radiological or endoscopic reduction of intussusception in a symptomatic child with intestinal obstruction from a PJS polyp. At laparotomy, patients should ideally undergo an intraoperative enteroscopy to clear the small bowel of other PJS polyps.

(strong recommendation, low-quality evidence, agreement 100%)

Recommendation 5

Elective polypectomy should be performed to prevent polyp-related complications. Small bowel polyps >1.5 to 2 cm in size (or smaller if symptomatic) should be electively removed to prevent intussusception. Endoscopic, surgical, and combined approaches all have their merit and the choice of modality should be made on a case by case basis, depending on the site and size of the polyp and the endoscopic expertise available.

(weak recommendation, low-quality evidence, agreement 100%)

Recommendation 6

LCCSCTs leading to feminizing manifestations including gynaecomastia are associated with the PJS and males should be assessed for this at clinical assessment. Referral to a paediatric endocrinologist is required in those that develop LCCSCT.

(moderate recommendation, low-quality evidence, agreement 100%)

Recommendation 7

There is no role for pharmacological agents as a treatment or for chemoprevention in PJS.

(strong recommendation, low-quality evidence, agreement 100%)

Recommendation 8

Cancer in children with PJS is an extremely rare event. Children and adolescents should be routinely clinically examined for features of sex cord tumours.

(Moderate recommendation, moderate-quality evidence, agreement 100%)

REFERENCES

1. Online Mendelian Inheritance in Man (OMIM). <https://omim.org/entry/175200>. Accessed June 2018.
2. Aretz S, Stienen D, Uhlhaas S, et al. High proportion of large genomic STK11 deletions in Peutz-Jeghers syndrome. *Human Mut* 2005;26:513–9.
3. Beggs AD, Latchford AR, Vasen HF, et al. Peutz-Jeghers syndrome: a systematic review and recommendations for management. *Gut* 2010;59:975–86.
4. Hinds R, Philp C, Hyer W, et al. Complications of childhood Peutz-Jeghers syndrome: implications for paediatric screening. *J Pediatr Gastroenterol Nutr* 2004;39:219–20.
5. Stratakis CA, Kirschner LS, Carney JA, et al. Clinical and molecular features of the Carney complex: diagnostic criteria and recommendations for patient evaluation. *J Clin Endocrinol Metab* 2001;86:4041–6.
6. Sarkozy A, Conti E, Digilio MC, et al. Clinical and molecular analysis of 30 patients with multiple lentigines LEOPARD syndrome. *J Med Genet* 2004;41:68.
7. Goldstein SA, Hoffenberg EJ. Peutz-Jegher syndrome in childhood: need for updated recommendations? *J Pediatr Gastroenterol Nutr* 2013;56:191–5.
8. Van Lier MGF, Mathus-Vliegen EMH, Wagner A, et al. High cumulative risk of intussusception in patients with Peutz-Jeghers syndrome: time to update surveillance guidelines? *Am J Gastroenterol* 2011;106:940–5.
9. Latchford AR, Neale K, Phillips RK, et al. Peutz-Jeghers syndrome: intriguing suggestion of gastrointestinal cancer prevention from surveillance. *Dis Colon Rectum* 2011;54:1547–51.
10. Spiegelman AD, Thomson JP, Phillips RK. Towards decreasing the relaparotomy rate in the Peutz-Jeghers syndrome: the role of preoperative small bowel endoscopy. *Br J Surg* 1990;77:301–2.
11. Barnard J. Screening and surveillance recommendations for paediatric gastrointestinal polyposis syndromes. *J Pediatr Gastroenterol Nutr* 2009;48:S75–8.
12. Tringali A, Thomson M, Dumonceau JM, et al. Paediatric gastrointestinal endoscopy: ESPGHAN and European Society of Gastrointestinal Endoscopy Guidelines. *J Pediatr Gastroenterol Nutr* 2017;64:133–53.
13. Caspari R, Von Falkenhausen M, Krautmacher C, et al. Comparison of capsule endoscopy and magnetic resonance imaging for the detection of polyps of the small intestine in patients with familial adenomatous polyposis or with Peutz-Jeghers' syndrome. *Endoscopy* 2004;36:1054–9.
14. Brown G, Fraser C, Schofield G, et al. Video capsule endoscopy in Peutz-Jeghers syndrome: a blinded comparison with barium follow-through for detection of small-bowel polyps. *Endoscopy* 2006;38:385–90.
15. Gupta A, Postgate AJ, Burling D, et al. A prospective study of MR enterography versus capsule endoscopy for the surveillance of adult patients with Peutz-Jeghers syndrome. *Am J Roentgenol* 2010;195:108–16.
16. Gastineau S, Viala J, Caldari D, et al. Contribution of capsule endoscopy to Peutz-Jeghers syndrome management in children. *Dig Liver Dis* 2012;44:839–43.
17. Chong AK, Chin BW, Meredith CG. Clinically significant small-bowel pathology identified by double-balloon enteroscopy but missed by capsule endoscopy. *Gastrointest Endosc* 2006;64:445–9.
18. Ross A, Mehdizadeh S, Tokar J, et al. Double balloon enteroscopy detects small bowel mass lesions missed by capsule endoscopy. *Dig Dis Sci* 2008;53:2140–3.

19. Soares J, Lopes L, Vilas Boas G, et al. Wireless capsule endoscopy for evaluation of phenotypic expression of small-bowel polyps in patients with Peutz-Jeghers syndrome and in symptomatic first-degree relatives. *Endoscopy* 2004;36:1060–6.
20. Postgate A, Despott E, Burling D, et al. Significant small-bowel lesions detected by alternative diagnostic modalities after negative capsule endoscopy. *Gastrointest Endosc* 2008;68:1209–14.
21. Fritscher-Ravens A, Shcherbakov PL, Bufler P, et al. Impact on management of small intestinal disorders by wireless capsule endoscopy in young children less than age 8: a European Multicenter Study. *Gastrointest Endosc* 2008;67:AB79.
22. Friedlander J, Liu QY, Sahn B, et al. NASPGHAN capsule endoscopy clinical report. *J Pediatr Gastroenterol Nutr* 2017;64:485–94.
23. Cohen SA, Ephrath H, Lewish JD, et al. Paediatric capsule endoscopy: review of the small bowel and patency capsules. *J Pediatr Gastroenterol Nutr* 2012;54:409–13.
24. Maccioni F, Al Ansari N, Mazzamuro F, et al. Surveillance of patients affected by Peutz-Jeghers syndrome: diagnostic value of MR enterography in prone and supine position. *Abdom Imaging* 2012;37:279–87.
25. Sadigh S, Chopra M, Sury MR, et al. Paediatric magnetic resonance enteroclysis under general anaesthesia—initial experience. *Pediatr Radiol* 2017;47:877–83.
26. Schulmann K, Hollerbach S, Kraus K, et al. Feasibility and diagnostic utility of video capsule endoscopy for the detection of small bowel polyps in patients with hereditary polyposis syndromes. *Am J Gastroenterol* 2005;100:27–37.
27. Pilleul F, Penigaud M, Milot L, et al. Possible small-bowel neoplasms: contrast-enhanced and water-enhanced multidetector CT enteroclysis. *Radiology* 2006;241:796–801.
28. Ohmiya N, Nakamura M, Takenaka H, et al. Management of small-bowel polyps in Peutz-Jeghers syndrome by using enteroclysis, double-balloon enteroscopy, and videocapsule endoscopy. *Gastrointest Endosc* 2010;72:1209–16.
29. Fallon S, Lopez M, Zhang W, et al. Risk factors for surgery in paediatric intussusception in the era of pneumatic reduction. *J Pediatr Surg* 2013;48:1032–6.
30. McGarrity TJ, Kulin HE, Zaino RJ. Peutz-Jeghers syndrome. *Am J Gastroenterol* 2000;95:596–604.
31. Hearle N, Schumacher V, Menko FH, et al. STK11 status and intussusception risk in Peutz-Jeghers syndrome. *J Med Genet* 2006;43:e41.
32. Panos RG, Opelka FG, Noguerras JJ. Peutz-Jeghers syndrome. A call for intraoperative enteroscopy. *Am Surg* 1990;56:331–3.
33. Sakamoto H, Yamamoto H, Hayashi Y, et al. Nonsurgical management of small-bowel polyps in Peutz-Jeghers syndrome with extensive polypectomy by using double-balloon endoscopy. *Gastrointest Endosc* 2011;74:328–33.
34. Gao H, Van Lier MG, Poley JW, et al. Endoscopic therapy of small-bowel polyps by double-balloon endoscopy in patients with Peutz-Jeghers syndrome. *Gastrointest Endosc* 2010;71:768–73.
35. Bizzarri B, Borrelli O, de'Angelis N, et al. Management of duodenal-jejunal polyps in children with Peutz-Jeghers syndrome with single-balloon enteroscopy. *J Pediatr Gastroenterol Nutr* 2014;59:49–53.
36. Gourgari E, Saloustros E, Stratakis CA. Large-cell calcifying Sertoli cell tumours of the testes in paediatrics. *Curr Opin Pediatr* 2012;24:518–22.
37. Robinson J, Lai C, Martin A, et al. Oral rapamycin reduces tumour burden and vascularization in Lkb1+/- mice. *J Pathol* 2009;219:35–40.
38. Kuwada SK, Burt R. A rationale for mTOR inhibitors as chemoprevention agents in Peutz-Jeghers syndrome. *Fam Cancer* 2011;10:469–72.
39. Hearle N, Schumacher V, Menko FH, et al. Frequency and spectrum of cancers in the Peutz-Jeghers syndrome. *Clin Cancer Res* 2006;12:3209–15.
40. Young RH, Welch WR, Dickersin GR, et al. Ovarian sex cord tumour with annular tubules: review of 74 cases including 27 with Peutz-Jeghers syndrome and four with adenoma malignum of the cervix. *Cancer* 1982;50:1384e402.
41. Song SH, Lee JK, Saw HS, et al. Peutz-Jeghers syndrome with multiple genital tract tumours and breast cancer: a case report with a review of literatures. *J Korean Med Sci* 2006;21:752–7.
42. Howell L, Bader A, Mullassery D, et al. Sertoli cell ovarian tumour and gastric polyps as presenting features of Peutz-Jeghers syndrome. *Pediatr Blood Cancer* 2010;55:206–7.
43. Van Lier M. High cancer risk and increased mortality in patients with Peutz-Jeghers syndrome. *Gut* 2011;60:141–7.
44. Shepherd NA, Bussey HJ, Jass JR. Epithelial misplacement in Peutz-Jeghers polyps. A diagnostic pitfall. *Am J Surg Pathol* 1987;11:743e9.
45. Patel K, Faiz O, Rutter M, et al. The impact of the introduction of formalised polypectomy assessment on training in the UK. *Frontline Gastroenterol* 2017;8:104–9.